

Original article

Taphonomy and palaeopathology in archaeozoology

Taphonomie et paléopathologie en zooarchéologie

László Bartosiewicz

*Department of Medieval Archaeology, Institute of Archaeological Sciences, Loránd Eötvös University,
Múzeum körút 4/B, 1088 Budapest, Hungary*

Received 28 September 2005; accepted 9 February 2006

Abstract

Taphonomy studies *post mortem* damage to animal bones. Palaeopathology is the study of *in vivo* lesions in the skeleton. Archaeozoology uses animal remains from archaeological sites to study the relationship between people and animals. The connection between these concepts is that while all archaeozoological finds are subject to some kind of taphonomic process, only a certain number originate from diseased animals. Palaeopathology developed special features in archaeozoology, since contemporary human interference must always be reckoned with in archaeological assemblages. Animal remains occur as scattered-food refuse so that most diagnoses are isolated from their biological context. This paper reviews through various examples why a taphonomic approach to palaeopathological studies is of utmost significance.

© 2007 Elsevier Masson SAS. All rights reserved.

Résumé

La taphonomie étudie la déprédation sur des os d'animaux après la mort. La paléopathologie est l'étude des lésions sur le squelette vivant. La zooarchéologie étudie le rapport entre animaux et humains à l'aide des restes d'animaux. Le rapport entre les trois approches est que chaque trouvaille zooarchéologique est soumise à un processus taphonomiques et seul un certain nombre d'entre elles provient d'animaux malades. La paléopathologie a développé des apports uniques en archéozoologie parce qu'il est nécessaire de tenir compte de l'interférence humaine contemporaine dans les collections archéologiques. Les restes d'animaux résultent de restes alimentaires diffus. À cause de cela, la plupart des éléments diagnostiques sont isolés de leur contexte biologique. Cet article examine, par des exemples divers, l'importance d'une démarche taphonomique appliquée aux études paléopathologiques.

© 2007 Elsevier Masson SAS. All rights reserved.

Resumen

A tafonómia tudománya az állatsontleletek *post mortem* károsodásait vizsgálja. A paleopatológia a csontváz kóros, *in vivo* zavarait kutatja. A régészeti állattan a régészeti lelőhelyek állatmaradványainak tanulmányozása az egykori ember-állat kapcsolatok jobb megértése céljából. E három terület kapcsolatát az jellemzi, hogy míg minden állatsontlelet tafonómiai változásokon esik át, csak viszonylag kevésen figyelhetők meg betegségek tünetei. A régészeti állattanban végzett paleopatológiai vizsgálatok sajátja, hogy a régészeti összefüggésben talált állatmaradványok esetében mindenkor számolnunk kell emberi hatással. Ugyanakkor ezek a leletek általában szétszórt ételhulladékként kerülnek napvilágra, ami azt jelenti, hogy biológiai összefüggéseikben nem tanulmányozhatjuk őket. A dolgozat példákon keresztül mutatja be, miért fontos a tafonómiai, leletképződési szempontok figyelembe vétele a régészeti állattani leletek paleopatológiai elemzése során.

© 2007 Elsevier Masson SAS. All rights reserved.

Keywords: Taphonomic preservation; Morbidity; Epiphyseal age; Bone density; Cultural influence

Mots clés : Conservation ; Morbidité ; Âge épiphyseal ; Densité de l'os ; Influence culturelle

E-mail address: H10459bar@helka.iif.hu.

0016-6995/\$ – see front matter © 2007 Elsevier Masson SAS. All rights reserved.

doi:10.1016/j.geobios.2006.02.004

1. Introduction

Taphonomy, as regards archaeozoology, is the study of *post mortem* processes which affect the following:

- the preservation, observation or recovery of dead organisms;
- the reconstruction of their biology or ecology;
- the reconstruction of the circumstances of their death (Haglund and Sorg, 1997: 13).

Of these points, the two latter are directly related to the physical condition and health of the animal. Palaeopathology is the study of *in vivo* lesions identified in the excavated material. Archaeozoology is the study of animal remains from archaeological sites, with regard to the relationship between people and animals. In addition to these three basic concepts, the term preservation in this paper is defined in a strictly taphonomic sense, meaning the degree of *post mortem* physical survival of individual-animal remains, in spite or because of pathological deformations. In other words, preservation in this paper does not refer to the presence or absence of lesions, but the primary, taphonomic preservation of the skeletal element in question.

Archaeozoology adopted the concept of taphonomy relatively recently from palaeontological research (Efremov, 1940; Lyman, 1994; Nicholson, 2001). Although palaeopathological phenomena have been described by palaeontologists since the mid-18th century (e.g., Marsigli, 1726; Esper, 1774), the first comprehensive book on this topic was published by Moodie (1923). Another major summary by Tasnádi Kubacska (1962) followed only three decades later. Archaeozoology adopted basic methods of palaeopathology from vertebrate palaeontology, but also combined them with methods from modern veterinary science, since most archaeological-bone specimens originate from domestic animals. Following over four decades of research by archaeozoologists across Europe that included the recording of pathological specimens as well, animal diseases in archaeology were first summarized in the seminal book by Baker and Brothwell (1980). Since then the Animal palaeopathology working group was formed in 1999 and formally recognised by the International council for archaeozoology.

Palaeopathology developed special features in archaeozoology, largely owing to the special taphonomic aspects of this latter discipline. In contrast to palaeontology, ancient human interference must always be reckoned with in archaeozoological assemblages as an integral and exciting part of biostratigraphy (Bartosiewicz, 2001). It is this phase of the taphonomic process during which contemporary cultural modifiers, of greatest interest from the viewpoint of archaeological interpretation, influence the look of the find assemblage.

Four interrelated aspects of this problem outlined here will be reviewed in the following four subchapters:

- the effect of deposition on diagnosis must always be reckoned with in archaeozoological pathology;

- the age of domestic animals is related to both their use by people and the *post mortem* preservation of skeletal parts displaying pathological lesions resulting from the way they were exploited;
- in addition to these complex cultural influences, the diseases themselves may alter the bone structure, thereby affecting preservation in the aforementioned general, taphonomic sense;
- various types of damage to the bone may be interpreted alternatively as having taken place *in vivo* or *post mortem* in terms of origins.

2. Results and discussion

2.1. Deposition and diagnosis

There is a fundamental taphonomic difference between the palaeopathology of humans and animals represented in archaeological contexts. Under ordinary circumstances, humans tend to be accorded proper burials that preserves the integrity of their skeletons. The skeletons of slaughtered animals are seldom found intact in archaeological contexts, owing to the massive culture-driven interference with their bodies. Animal bones, therefore, most commonly occur as disarticulated and dispersed or re-deposited food refuse at archaeological sites. Consequently, in archaeozoological assemblages most diagnoses must be made on single fragments that have been isolated from the biological context (age, sex, syndromes) of the individual, that is, its skeleton.

Animal remains from archaeological sites are selectively preserved to different degrees in and of themselves, but palaeopathological studies are especially hard hit by the lack of complementary information concerning soft tissue or even the rest of the skeleton.

Aside from the occasional discovery of animal skeletons deposited as a whole (frequently for no tangible, so-called “ritual” reasons or any animal carcasses not used for human consumption and dumped as a whole; Fig. 1), AD 4th to 10th horse (*Equus caballus* Linnaeus, 1758) burials represent a special category in Hungary. Owing to the largely Migration period mortuary practice that often involved sacrificing and burying entire horses together with humans or sometimes by themselves, the remains of this domestic animal are comparable to the human skeletons found in graves from a taphonomic and methodological point of view: their age, sex and stature can all be identified, thereby providing a relatively complete profile of each individual animal. A comparative study of complete skeletons from 232 human and 131 horse burials has shown that multiple lesions were similarly distributed over the skeletons of these two species (Fig. 2), usually buried intact (Bartosiewicz, 2002). The implications of this observation are evident: given full *post mortem* skeletal preservation, similar to that of most human burials, much more could be said about animal disease than on the basis of isolated, single bone fragments. In other words, this similarity between humans and horses does not stem from comparable mortality patterns, but from comparably favourable taphonomic circumstances.

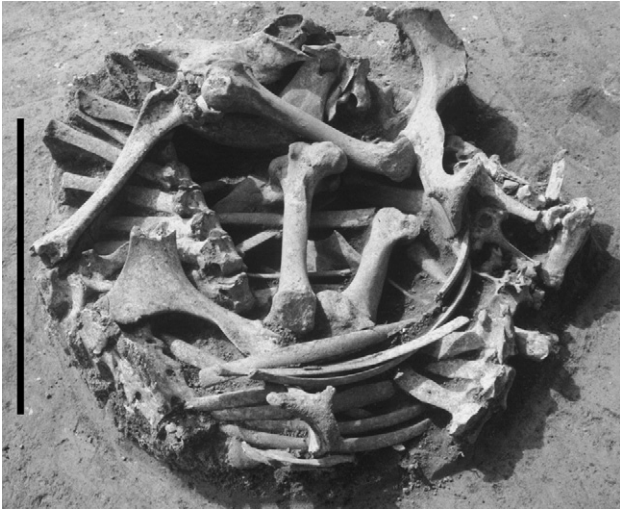


Fig. 1. Complete cattle burial at the Late Neolithic site of Csabdi-Télizöldes (Hungary). The animal was curled up tightly in a small pit. Its skull and the orbit may be seen at the top of the picture, near the left knee. Scale bar = 500 mm.

Such comprehensive skeletal evidence, however, is usually not available in the case of food remains recovered from settlements. This type of massive taphonomic loss, hampering holistic interpretation, must be considered in the evaluation of animal disease in archaeology.

2.2. Age, morbidity and taphonomic preservation

The animal's age at death is an important factor behind bone preservation. Bone density, that is, mineral content steadily increases during life, although longitudinal bone growth terminates when epiphyseal plates ossify. This relationship can be easily demonstrated in the most common domestic animals by plotting preservation scores of various bones (1 = worst; 3 = best; von den Driesch, 1976: 7, Table 1) against the relevant ages of epiphyseal fusion (Schmid, 1972: 75, Table IX).

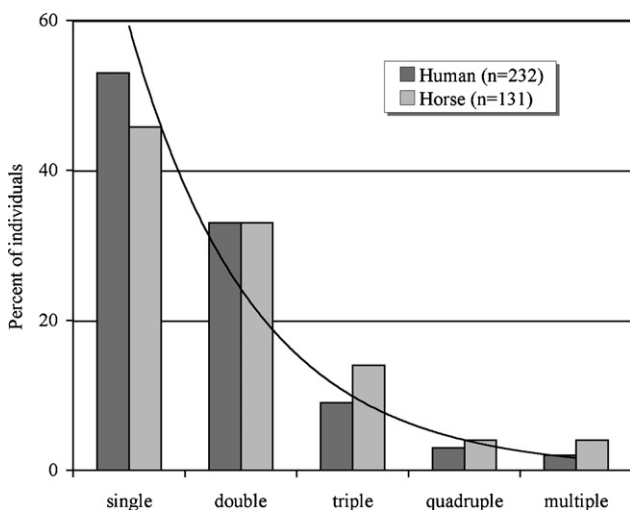


Fig. 2. Frequency of pathological lesions per individual in the burials of humans and horses.

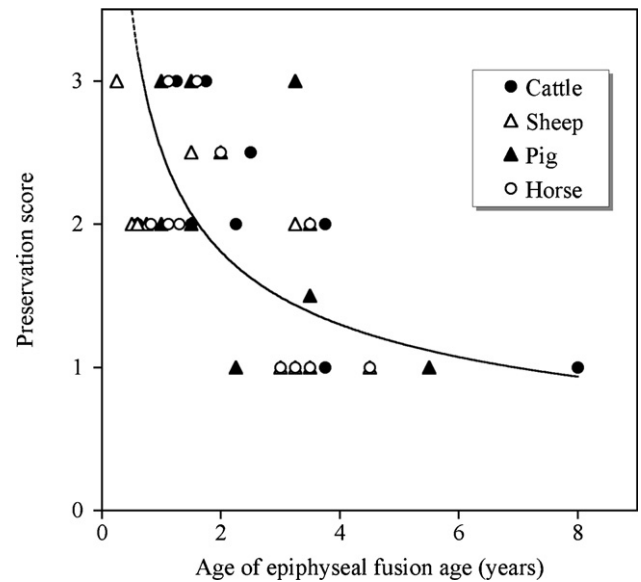


Fig. 3. Relationship between the age of epiphyseal fusion (Schmid, 1972: 75, Table IX) and taphonomic preservation by animal species (von den Driesch, 1976: 7, Table 1).

It must be emphasised here that empirical preservation scores listed by Angela von den Driesch do not refer to any kind of pathological condition. They simply mean the probability by which a particular bone part may be found in a measurable condition: and this is related to age. The resulting graph (Fig. 3) shows that, regardless of animal species, early fusing long bone parts (e.g. proximal metapodia) are also the most likely to be well preserved in a general, taphonomic sense. In spite of the differences between the natural life spans of cattle (*Bos taurus* Linnaeus, 1758), sheep (*Ovis aries* Linnaeus, 1758), pig (*Sus domesticus* Erxl., 1777) and horse, the general tendency is clear.

The implications of this relationship are twofold. On one hand, the remains of older animals and especially their “older” (i.e., early fusing) skeletal parts within the same individual stand a better chance of *post mortem* preservation. On the other hand, with the advancement of age, animals are also increasingly prone to develop pathological lesions. Among these, the most common symptoms are encountered on the best-preserved, early-fusing bones. This introduces a systematic taphonomic bias in the palaeopathological evaluation of excavated animal bones.

One of the domestic animals under discussion here, the pig, is unique as an animal kept exclusively for its primary product, pork. Meat purpose animals (even among cattle or sheep) tend to be slaughtered at relatively early ages, once their keeping costs more than the gain that may be expected. In addition, pig is more prolific than the other uniparous ungulates discussed in this study, and can thus be culled in greater numbers without jeopardising reproduction on a herd level. Consequently, the average age at death for pigs tends to be low both in absolute and relative terms in most archaeozoological assemblages. As a result, pigs tend to look “healthier” than other animals: many of them simply do not live long enough to develop chronic diseases that would be grave enough to deform their skeletons. Although even young pigs may suffer acute conditions such as

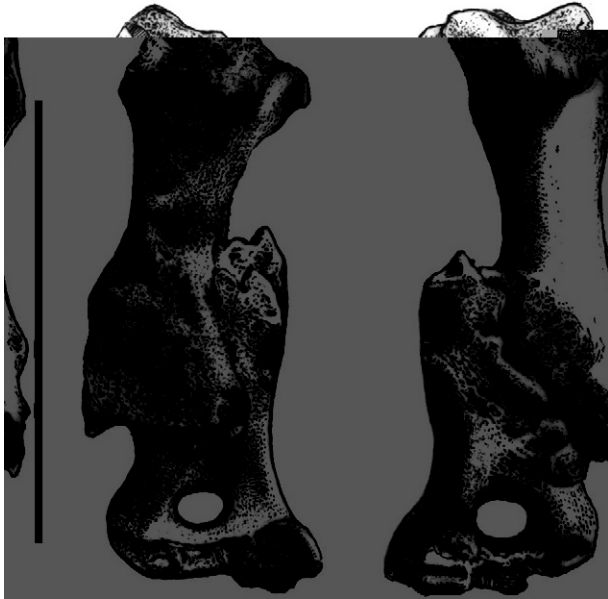


Fig. 4. Humerus fracture healed with dislocation in a Roman Period piglet from Ács-Vaspuszta, (Hungary). Left: anterior aspect, right: posterior aspect. Scale bar = 50 mm.

trauma (Fig. 4), their bones are often not resistant enough to be preserved and thus, recovered. This creates a taphonomic bias in pathological analyses. It is important to note the direct effect of ancient human decisions (in this case slaughtering pigs at a young age) on the development, manifestation and archaeological detectability of palaeopathological phenomena.

Secondary exploitation (Sherratt, 1981), that is, the use of domestic animals beyond meat consumption, increased the incidence of lesions on their bones. Draught animals, as well as

those reared for wool, milk or ritual purposes are, by definition, kept alive for a relatively long time, often culled only when they become useless in their secondary function. In the not so distant past, animals may have attained ages rarely seen in present-day domestic animals (Baker and Brothwell, 1980: 136). Due to their late manifestation and indirect impact on commercial production, degenerative bone disorders have less time to fully develop under the circumstances of high-intensity modern farming, where feeble individuals easily end up culled.

While not a pathological agent in and of itself, age as a systemic background factor contributes to morbidity in animals in at least three major ways:

- *natural aging*: many pathological processes of the skeleton are promoted by the declining blood supply to bone (Sokoloff, 1963: 97) that tends to lead to deteriorating regeneration capacity;
- *repetitive strain syndrome* (RSI) in working animals is cumulative through time. Most degenerative changes in the articular cartilage are caused by a combination of age and inherited constitution as well as repeated trauma which results in a “loss of harmony between form and function” (Baker, 1978: 110). Degenerative joint disease usually affects the weight-bearing joints (Steinbock, 1976: 278);
- *longevity* in animals exploited for secondary products also increases the risks of acute trauma in simple, probabilistic terms.

The diagnosis of bone deformations caused by overworking in draught cattle offers commonly-occurring archaeozoological examples of the relationship between age, *in vivo* pathological lesions and their *post mortem* preservation. Symptoms of chronic arthritis, such as the fusion of the hock joint (spavin,

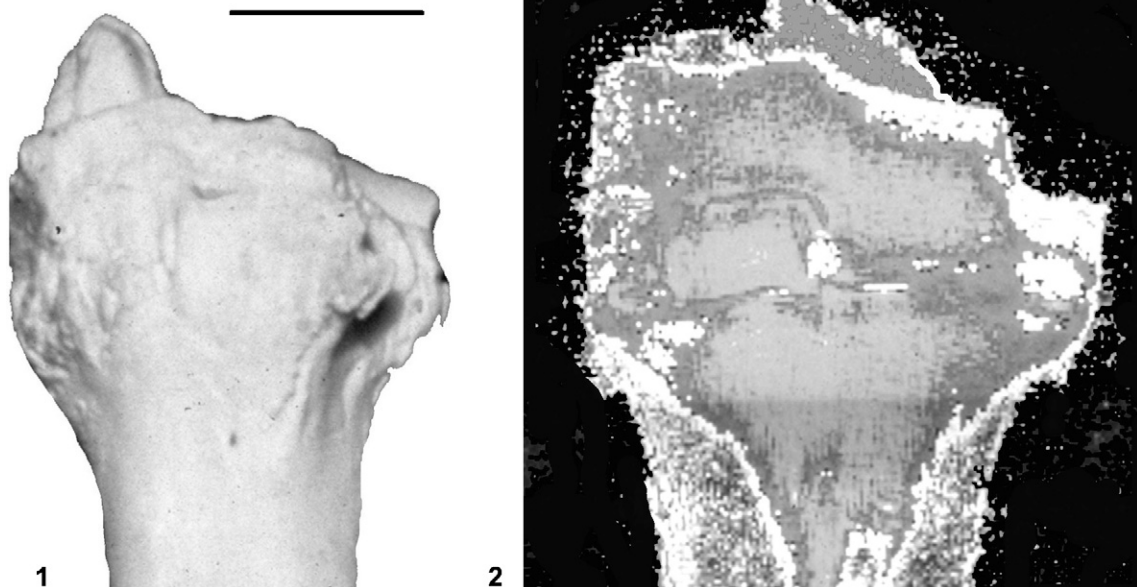


Fig. 5. 1. Fusion of tarsal and metatarsal bones (spavin) in the hock joint of a modern draught ox (Romania). Anterior aspect. 2. MRI image of spavin in the hock joint of the same modern draught ox. White areas are too dense to have even shown water content, light shades of gray indicate lowest density. Scale bars = 50 mm.

ostitis rarefaciens et condensans), are widely known on the archaeological finds of cattle. In a sample of present day draught oxen from Romania (Bartosiewicz et al., 1997b: 71, Table 21) this condition occurred exclusively above eight years of age (and a live weight of 475 kg; Fig. 5(1)). The magnetic resonance image (MRI, Bartosiewicz et al., 1997a) of the same bone (Fig. 5(2)) shows the increased density of fused surfaces between the tarsal bones and the proximal end of the metatarsus. This pathological condition, developing under human influence, increases the chances of bone preservation after the animal's death, thereby creating a "pathological" bias in taphonomic analyses.

2.3. Diseases influencing taphonomic bone preservation

Similarly to the age-dependent, *in vivo* increase in bone mineral content, many diseases interfere with bone metabolism directly affecting *post mortem* bone preservation. Based on a tabulated summary by Baker (1978: 108, Fig. 35), it is clear that osteoporosis with decreasing bone mass and/or inorganic mineral content as well as osteomalacia with a relative increase in the organic component are symptoms that would subsequently counteract bone preservation in the archaeological deposit and as such, will be underrepresented in excavated assemblages. Even if pathologically osteoporotic bones are present in archaeological materials, their condition may sometimes be mistaken for fossil diagenesis such as postdepositional chemical leaching.

Heavily-infected, poorly-healed compound fractures, as well as various forms of neoplasia may result in the expansion of bone volume at the expense of density. Primary, malignant tumours usually develop during the period of intensive growth, therefore such bones are rarely preserved. Some tumours, on the other hand, develop aggressively and penetrate the bone, forming an organic complex. In such cases, chances of taphonomic preservation may become somewhat better (Fig. 6).

An exacerbation of age-related increase in the mineral component of bones has already been discussed in relation to draught exploitation. On the basis of its anatomical location natural RSI, rather than metabolic reasons may lay behind the extreme thickening of the cranial articular surface of a Copper Age sheep axis found at Horum Höyük, Turkey (Fig. 7). While the increased density and swollen outline of the collar-shaped *facies articularis* falls short of osteopetrosis, this hypertrophic lesion may have been caused by repeated impact in "shock combat" between rams. Cervical vertebrae in 14 feral Soay rams from the Outer Hebrides (Scotland) showed acute trauma, apparently linked with this sex-dependent behaviour (Clutton-Brock et al., 1990: 8 and 12, Plates 8, 9). These symptoms never occurred in females from the same herd.

Avian leucosis associated with a number of viral strains is a type of animal osteopetrosis in its classical form. It occurs relatively frequently in archaeological assemblages of chicken (*Gallus domesticus* Linnaeus, 1758) bones (Fig. 8; Gál, 2004), and historical epidemiological studies of the problem have also been initiated (Brothwell, 2001: 318). In this case, the extreme *in vivo* increase in bone mass contributes to the good *post*

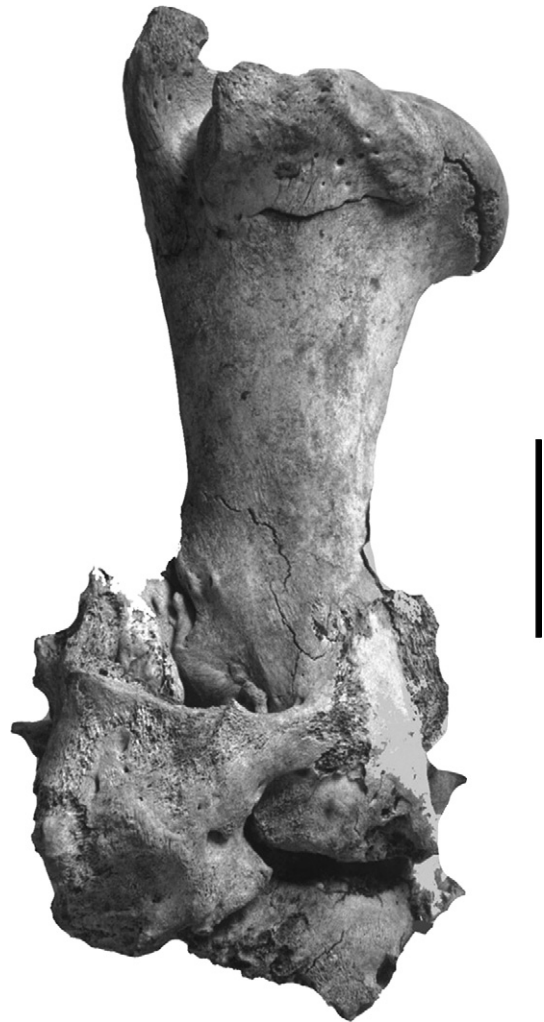

Fig. 6. Porous tumour in the right elbow joint of a young neolithic cattle from Csabdi-Télizöldes, (Hungary). Anterior aspect. Scale bar = 50 mm.

mortem preservation of otherwise relatively fragile bird bones. As opposed to osteopetrosis (a pathological buildup of inorganic minerals within the bone tissue that also leads to external deformation; Baker and Brothwell, 1980), fossilisation leaves the appearance of bones intact.

It is worth to mention that, in certain cultures, death by pathological causes (rather than proper slaughtering) may reduce the culinary value of meat or render the entire carcass useless (G.K. Knust, comment in review). This may result in differential treatment, including the lack of butchery thus, in a broad sense, potentially enhancing the *post mortem* preservation of skeletal parts.

2.4. Interpreting bone damage

Given the selective taphonomic loss of information hampering palaeopathological studies, questions of equifinality (Lyman, 1994) are of lesser concern here. One of the special problems, however, is posed by symptoms of *perimortem* trauma, that is, bone injury directly related to, or at least

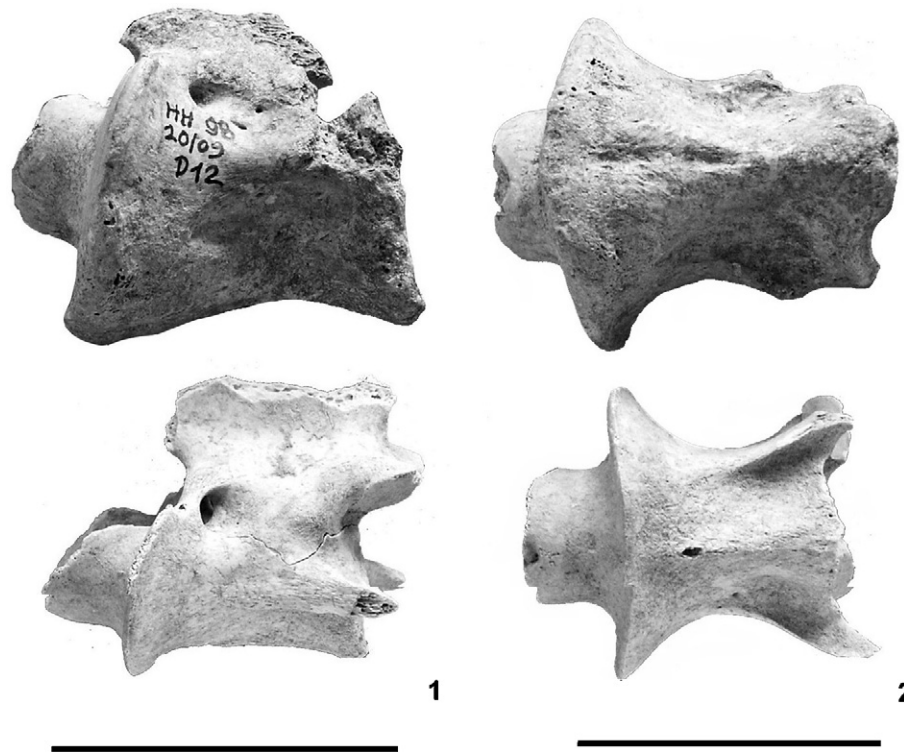


Fig. 7. 1. Osseous hypertrophy in the axis of a Copper Age sheep, Horum Höyük (Turkey). Lateral view (The specimen below originates from a healthy individual). 2. Osseous hypertrophy in the same sheep axis. Ventral view (The specimen below originates from a healthy individual). Scale bars = 50 mm.

simultaneous with, the actual cause of death. Such damage to the bone tissue represents a borderline case: it displays no diagnostic evidence of healing and is thus often morphologically indistinguishable from true, *post mortem* taphonomic modifications (Bartosiewicz, 1999). Even in forensic taphonomy, in which high precision is a legal matter, it is only the absence of healing that may rule out premortem trauma, while the sharpness of the fragment or the cut edge may vary depending on the amount of surface erosion in excavated materials. In the case of *peri-* v.s. *post mortem* bone fracture references are made to the surface colour and edge characteristics of the bone fragment. In terms of cut marks, however, distinguishing between old cuts and those inflicted during the course of excavation or in the laboratory have been discussed in the literature (White and Folkens, 2000: 409, 419–420; Ubelaker, 1997).

In addition to the better known difficulty of distinguishing non-healed bone fractures from *post mortem* fragmentation, a special type of this injury is of relevance here. Cutmarks on the ventral side of the first two cervical vertebrae (atlas and axis) have been commonly interpreted as *perimortem*, that is, related to cutting the animal's throat. This type of injury was observed, for example, on the atlas of both a sheep and a goat at Late Bronze Age Kamid el-Loz (Lebanon, Bökönyi, 1985: Taf. 85/1-2) and on the articulated atlas and axis of a ca. 800 BC pig from Tell es-Salihyeh (Syria, Lepiksaar, 1990: 117). Such transversal cutmarks were also discovered on a small camelid (*Lama* cf. *pacos*) atlas from the 15th century, Inca period site of Incarracay (Cochabamba Valley, Bolivia). This bone is damaged by fine transversal cutmarks in the region where

the *membrana atlantooccipitalis ventralis* originates (Fig. 9). Therefore they may be alternatively explained by either slaughtering or patterned carcass partitioning. The information that in pre-conquest Perú, sacrificial animals were killed by tearing their hearts out (Fig. 10) is of special relevance here. Slitting the animal's throat was considered a distinctly non-traditional, that is, Christian way of killing the animals: “*Que no mate acá, cino como en este tienpo de cristiano que degüelle el pescueso del carnero...* (“Do not kill it this way, but do it like the Christians nowadays, by cutting the ram's neck...”; Poma de Ayala [1990]: 160)”.

Distinguishing between *perimortem* or *post mortem* cut marks on bone is hopeless within a six-days interval (K. McSweeney, pers. com.), which is well beyond the time span of traditional meat processing. Therefore, the anatomical location of such cuts is often considered as indirect evidence. Gilbert (1988: 85, Fig. 5, Pl. XIV/1-4) was the first to distinguish two kinds of cutmarks on sheep atlases from Godin Tepe (Iran, ca. 2600–1500 BC):

- cuts running from across the ventral surface after having penetrated the throat's soft tissue, were probably made during the animal's slaughter and (= *perimortem* trauma);
- cuts on the anterior edge of the *fovea articularis cranialis* are possibly caused by subsequent (that is, *post mortem*) decapitation by humans as “taphonomic agents”.

Somewhat contradicting the aforementioned culturally idiosyncratic mode of slaughtering, the small camelid atlas under discussion here is damaged by the second type of cuts.

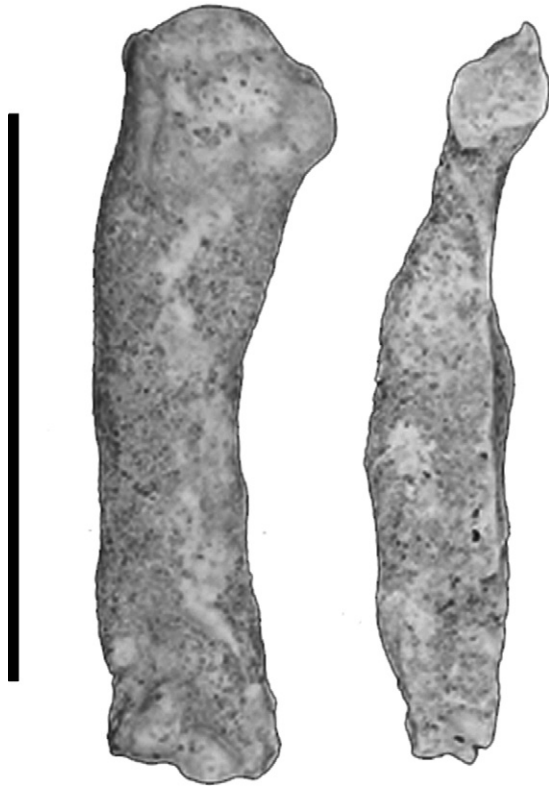

Fig. 8. Deformations caused by osteopetrosis on a medieval chicken humerus (on the left) and ulna from Buda-Teleki Palace (Hungary). Scale bar = 50 mm.



Fig. 10. Killing a lama the traditional way in Peru, as depicted by Poma de Ayala (1615).

Compared to these enigmatic cutmarks, *de facto* pseudopathologies may be caused by a variety of taphonomic factors. There is a host of agents of both geological (e.g., soil corrosion, sedimentary deformations, abrasion by water and sediments) and bionic origins (e.g., *post mortem* effects of bacteria and fungi, root etching, mollusc and insect damage) that may be mistaken for pathological lesions (Y. Fernández-Jalvo, comment in review). A detailed, systematic discussion of pseudopathologies, however, would require a separate study

and was thus considered beyond the focus of this paper. This very broad problem can be dealt with here only anecdotically, using a single, rather spectacular example. There is some similarity between *post mortem* rodent gnawing (Fig. 11) and arthrotic grooving caused by bone fragments caught *in vivo* within the joint, often referred to as “mouse” (*corpus liberum [mus] articuli*; Fig. 12). Carnivore and pig gnaw marks, more destructive and less patterned than those made by rodents, are somewhat reminiscent of bone necrosis on excavated specimens.

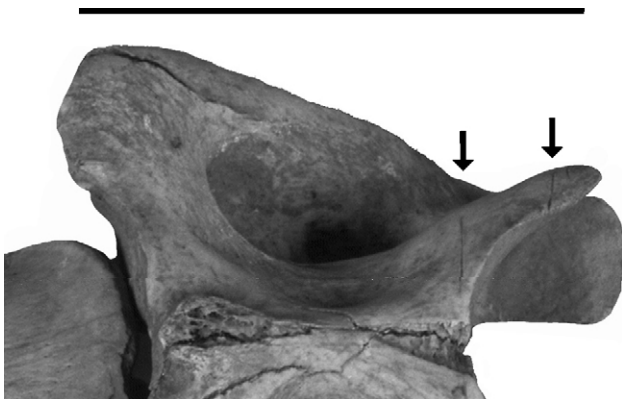

Fig. 9. Small camelid atlas with cutmarks from the 16th century (Cochacamba Valley, Bolivia). Ventral aspect. Scale bar = 50 mm.




Fig. 11. Squirrel (*Sciurus vulgaris* Linnaeus, 1758): gnawing on the diaphysis of a Bronze Age red deer (*Cervus elaphus* Linnaeus, 1758) metatarsal from Parte (Ljubljana Marshland, Slovenia). Lateral aspect. Scale bar = 20 mm.



Fig. 12. Arthrotic grooving caused by “mouse” on the distal articular end of a left humerus in Copper Age cattle (*Bos taurus* Linnaeus, 1758) from Győr-Szabadrét-domb. Scale bar = 50 mm.

3. Conclusions

The examples reviewed in this paper serve to reconfirm the following points set out at the beginning of this study:

- animal palaeopathology in archaeozoology most commonly has to rely on diagnoses based on single bone specimens;
- older animals have a higher natural bone mineral content, while longevity concomitant with secondary exploitation, also results in more chronic bone deformations and a greater statistical probability of trauma;
- certain diseases directly affect bone mineral content thereby influencing differential *post mortem* preservation, that is, the selective identification of pathological conditions;
- aside from the problems of in depth veterinary interpretation, pathological phenomena are sometimes difficult to understand even from a simple, taphonomic point of view.

This paper contains a concise review of the way taphonomic phenomena and pathological lesions interact with each other on vertebrate remains. The examples cited here are archaeozoological, since there was a greater probability that domestic animals in the past suffered and survived animal disease, the marks of which then have a chance of showing up on the faunal remains from archaeological sites.

Acknowledgements

Grateful thanks are due to J. Antoni, A.M. Choyke, E. Gál, J. Gyarmati, T. Lauko and K. Pálfai who contributed photographs

to this paper. The French abstract was kindly translated by A. Bartosiewicz. Kind help by Y. Fernandez-Jalvo and G.K. Kunst, who reviewed this paper, is also acknowledged here. The presentation of this article was supported by Grant T047228 of the Hungarian Scientific Research Fund (OTKA) entitled “Anatomical and pathological investigations on the skeleton of domestic animals: the use of recent observations in the interpretation of archaeological finds”.

References

- Baker, J.R., 1978. The differential diagnosis of bone disease. In: Brothwell, D.R., Thomas, K.D., Clutton-Brock, J. (Eds.), *Research problems in zooarchaeology*. Institute of Archaeology, Occasional Publication 3, London, pp. 107–112.
- Baker, J.R., Brothwell, D.R., 1980. *Animal diseases in archaeology*. Academic Press, London.
- Bartosiewicz, L., 1999. Animal bones from the Cochabamba Valley, Bolivia. In: Gyarmati, J., Varga, A. (Eds.), *The Chacaras of War. An Inka site estate in the Cochabamba Valley, Bolivia*. Museum of Ethnography, Budapest, pp. 101–109.
- Bartosiewicz, L., 2001. Archaeozoology or zooarchaeology? A problem from the last century. *Archaeologia Polona* 39, 75–86.
- Bartosiewicz, L., 2002. Palaeopathology: similarities and differences between animals and humans. *Anthropológiai Közlemények* 43, 29–37.
- Bartosiewicz, L., Demeure, R., Mottet, I., Van Neer, W., Lentacker, A., 1997a. Magnetic resonance imaging in the study of spavin in recent and subfossil cattle. *Anthropozoologica* 25/26, 57–60.
- Bartosiewicz, L., Van Neer, W., Lentacker, A., 1997b. Draught cattle: their osteological identification and history. *Koninklijk Museum voor Midden-Afrika, Annalen. Zoologische Wetenschappen* 281, 1–147.
- Bökönyi, S., 1985. Tierknochenfunde aus dem Bereich der Werkstatt von Kamid el-Loz. In: Frisch, G., Mansfeld, G., Thiele, W.-R. (Eds.), *Kamid el-Loz. 6. Die Werkstätten der spätbronzezeitlichen Palaste*. Saarbrücker Beiträge zur Altertumskunde 33, pp. 199–205.
- Brothwell, D.R., 2001. Ancient avian osteopetrosis: the current state of knowledge. *Acta zoologica cracoviensia* 45 (special issue), 315–318.
- Clutton-Brock, J., Dennis-Bryan, K., Armitage, P.L., Jewell, P., 1990. Osteology of the Soay sheep. *Bulletin of the British Museum of Natural History (Zoology)* 56, 1–56.
- Driesch, A. von den, 1976. *Das Vermessen von Tierknochen aus vor- und frühgeschichtlichen Siedlungen*. Institut für Paläoanatomie, Domestikationsforschung und Geschichte der Tiermedizin der Universität München.
- Efremov, I.A., 1940. Taphonomy: a new branch of paleontology. *Pan-American Geologist* 74, 81–93.
- Esper, J.F., 1774. *Ausführliche Nachrichten von neuentdeckten Zoolithen unbekannter vierfüßiger Thiere*. Georg Wolfgang Knorr, Nürnberg.
- Gál, E., 2004. Broken-winged: fossil and subfossil pathological bird bones from recent excavations. In: Paper delivered at the International Conference of the Animal Palaeopathology Working Group of the International Council for Archaeozoology (ICAZ), Nitra, Slovakia, 23rd–24th September 2004.
- Gilbert, A.S., 1988. Zooarchaeological observations on the slaughterhouse of Meketre. *The Journal of Egyptian Archaeology* 74, 69–89.
- Haglund, W.D., Sorg, M.H., 1997. Method and Theory of forensic taphonomy research. In: Haglund, W.D., Sorg, M.H. (Eds.), *Forensic Taphonomy: The Postmortem Fate of Human Remains*. CRC Press LLC, Boca Raton FL, pp. 13–25.
- Lepiksaar, J., 1990. Die Tierreste vom Tell es-Salihyeh in Südsyrien. In: Schibler, J., Sedlmeier, J., Spycher, H.-P. (Eds.), *Festschrift für Hans R. Stampfli. Beiträge zur Archäozoologie, Archäologie, Anthropologie, Geologie und Paläontologie*. Helbing & Lichtenhahn, Basel, pp. 115–120.
- Lyman, R.L., 1994. *Vertebrate Taphonomy*. Cambridge Manuals in Archaeology. Cambridge University Press, Cambridge.
- Marsigli, L.F., 1726. *Danubius pannonicus mysicus*, 2. Amstelodam, Haga.
- Moodie, R.L., 1923. *Paleopathology: An Introduction to the Study of Ancient Evidences of Disease*. University of Illinois, Urbana, Illinois.

- Nicholson, R.A., 2001. Taphonomic investigations. In: Brothwell, D.R., Polard, A.M. (Eds.), *Handbook of Archaeological Sciences*. John Wiley and Sons Ltd, Chichester, pp. 179–190.
- Poma de Ayala, F.G., 1990. *Perui képes krónika* (El primer nueva crónica y buen gobierno). Gondolat, Budapest.
- Schmid, E., 1972. *Atlas of animal bones-Knochenatlas*. Elsevier Publishing Company, Amsterdam, London, New York.
- Sherratt, A., 1981. Plough and pastoralism: aspects of the secondary product revolution. In: Hodder, I., Isaac, G., Hammond, N. (Eds.), *Pattern of the past: studies in honour of David Clarke*. Cambridge University Press, Cambridge, pp. 261–305.
- Sokoloff, L., 1963. The biology of degenerative joint disease. *Perspectives in Biological Medicine* 7, 94–106.
- Steinbock, R.T., 1976. *Paleopathological diagnosis and interpretation*. Charles C. Thomas, Springfield, Illinois.
- Tasnádi Kubacska, A., 1962. *Paläopathologie. Pathologie der vorzeitlichen Tiere*. Gustav Fischer, Jena.
- Ubelaker, D., 1997. Taphonomic Applications in Forensic Anthropology. In: Haglund, W.D., Sorg, M.H. (Eds.), *Forensic Taphonomy: The Postmortem Fate of Human Remains*. CRC Press LLC, Boca Raton FL, pp. 77–91.
- White, T.D., Folkens, P.A., 2000. *Human Osteology*, 2nd Edition. Academic Press, New York.